

Creation of a neovagina in Rokitansky syndrome: comparison between two laparoscopic techniques

Stefano Bianchi, M.D.,^a Giada Frontino, M.D.,^b Nevio Ciappina, M.D.,^b Elisa Restelli, M.D.,^b and Luigi Fedele, M.D.^b

^a Clinica Ostetrica e Ginecologica I, Università di Milano, Ospedale San Giuseppe, Milan; and ^b Clinica Ostetrica e Ginecologica I, Università di Milano, Fondazione Istituto Di Ricovero e Cura a Carattere Scientifico Policlinico Mangiagalli e Regina Elena, Milan, Italy

Objective: To compare Vecchietti's and Davydov's laparoscopic techniques for creation of a neovagina in patients with Rokitansky syndrome.

Design: Comparative retrospective study.

Setting: Tertiary referral center for the treatment of Rokitansky syndrome.

Patient(s): Eighty patients with Rokitansky syndrome.

Intervention(s): Patients underwent surgical creation of a neovagina. Fifteen patients who underwent the Vecchietti procedure from October 2003 to December 2004 and 30 patients who underwent the Davydov procedure from June 2005 to August 2008 were also included from two previously published studies. Follow-up lasted at least 12 months.

Main Outcome Measure(s): Intraoperative parameters and anatomic results were compared. Functional results were compared through the Female Sexual Function Index. Epithelization of the neovagina was assessed in both groups through vaginoscopy and Schiller's test.

Result(s): No major intraoperative complications were encountered in either group. Mean (\pm SD) duration of surgery was 30 ± 9.6 and 134 ± 24 minutes in Vecchietti's and Davydov's approach, respectively. At 12 postoperative months, length and width of the neovagina in the two groups were 7.5 ± 1.1 and 2.8 ± 0.6 cm, and 8.5 ± 1.6 and 2.8 ± 0.65 , respectively. Epithelization of the neovagina at 6-month follow-up was 60% and 80%, respectively, and 100% in both groups at 12 postoperative months.

Conclusion(s): Anatomic and functional outcomes of the two approaches tend to be comparable at 12-month follow-up; the only significant difference seems to be in greater length for the neovagina obtained by Davydov's approach. (Fertil Steril® 2011;95:1098–100. ©2011 by American Society for Reproductive Medicine.)

Key Words: Rokitansky syndrome, Davydov, Vecchietti, laparoscopy, neovagina, sexual function, FSFI

Numerous surgical and nonsurgical techniques have been proposed for the creation of a neovagina in patients with Mayer-Rokitansky-Küster-Hauser (MRKH) syndrome. New surgical methods have recently been developed in which laparoscopy has replaced traditional surgery. Among these has been suggested sigmoid colpopoiesis (1–3), although Fedele's modified Vecchietti technique (4) and Davydov's method modified by Adamyan et al. (5) and by Soong et al. (6) are the two most adopted laparoscopic procedures. Because of the absence of comparative studies it is not clear which presents the most advantages. This report compares the two techniques in terms of safety and effectiveness.

MATERIALS AND METHODS

In this retrospective study, all patients with MRKH syndrome in a tertiary referral center for the treatment of Rokitansky syndrome who underwent Vecchietti's modified creation of a neovagina between October 2003 and May 2005 were compared with patients who underwent Davydov's modified technique between June 2005

Received September 22, 2010; revised and accepted November 10, 2010; published online December 17, 2010.

S.B. has nothing to disclose. G.F. has nothing to disclose. N.C. has nothing to disclose. E.R. has nothing to disclose. L.F. has nothing to disclose.

Reprint requests: Luigi Fedele, M.D., Clinica Ostetrica e Ginecologica I, Università di Milano, Fondazione IRCCS Cà Granda Ospedale Maggiore Policlinico, Via Commenda 12, 20122 Milan, Italy (E-mail: luigi.fedele@unimi.it).

and May 2009. Only one patient with a pelvic kidney, who belonged to the second group of patients, underwent Vecchietti's method and was therefore excluded from the study.

After the start of sexual activity, which was allowed 1 month after surgery, the use of dilators was recommended for shorter periods of time, depending on the frequency of intercourse as well as width, length, and epithelization of the neovagina.

The length and width of the neovagina were measured by using different sizes of dilators of different caliber. Quality of sexual function was measured through the evaluation of the Female Sexual Function Index (FSFI) (7) at 12 months after the surgical procedure.

The epithelization of the neovagina with stratified, squamous, and glycogen-containing epithelium was assessed through vaginoscopy and Schiller's test 6 and 12 months after surgery. Epithelization was quantified by dividing the neovaginal walls into four main quadrants: anterior, posterior, and two lateral. Each quadrant was assessed for the percentage of mature vaginal epithelial coverage after application of Schiller's iodine, and a total percentage was calculated by summing each quadrant's percentage of coverage. Follow-up lasted at least 12 months in both groups.

Additional information on methods is provided in the [Supplemental Material](#) (available online).

RESULTS

Mean age of the patients was 20.4 ± 3.4 years for the Vecchietti group and 20 ± 4.9 years for the Davydov group. Mean body

TABLE 1

Comparison between laparoscopic Davydov and Vecchietti techniques for the creation of a neovagina in patients with MRKH syndrome.

| Parameter | Vecchietti (n = 40) | Davydov (n = 40) |
|--|---------------------|------------------|
| Mean duration of surgery (min) ^a | 30 ± 9.6 | 134 ± 24 |
| Mean hospital stay (d) ^a | 8.5 ± 1.9 | 4.0 ± 1 |
| Intraoperative complications | None | None |
| Need for postoperative analgesia (d) | 8.5 ± 1.2 | 4.0 ± 2 |
| Postoperative vaginal bleeding (pads per day) | 3.2 ± 0.6 | 2.4 ± 0.4 |
| Length of neovagina at hospital discharge (cm) ^b | 6.3 ± 0.7 | 7.25 ± 2.1 |
| Length of neovagina at 12-mo follow-up (cm) ^b | 7.5 ± 1.1 | 8.5 ± 1.6 |
| Width of neovagina at hospital delivery (cm) ^c | 2.1 ± 0.5 | 2.0 ± 0.5 |
| Width of neovagina at 12-mo follow-up (cm) ^c | 2.8 ± 0.6 | 2.8 ± 0.65 |
| Urinary catheter removal (d) | 8.6 ± 0.2 | 2.1 ± 0.2 |
| Vaginal stenosis requiring second surgery | None | None |
| Epithelization of the neovagina at 12-mo follow-up (surface) (%) | 100 | 100 |

Note: Values are mean ± SD unless otherwise noted.
^a P < .001.
^b P < .05.
^c P > .05.

Bianchi. Techniques and instrumentation. Fertil Steril 2011.

mass index in the Vecchietti group was 25.8 kg/m², and in the Davydov group it was 22.6 kg/m². Mean diameter of the uterine remnants was 24 mm. No major intraoperative complications were encountered. Table 1 describes the various parameters assessed for the two techniques. Despite the possibility for patients operated with the Vecchietti approach to be discharged from the hospital at 48–72 hours after surgery, most of the patients in this case series lived at a considerable distance from our hospital (i.e., in other regions of the country), so that the mean hospital stay for this technique is seemingly higher than it should be. Although the duration of surgery was significantly longer for patients operated with Davydov's technique, all parameters regarding the postoperative course (duration of hospitalization, use of analgesics, and removal of the urinary Foley catheter) show an advantage for this approach.

In patients who underwent Vecchietti's procedure, oral analgesics were only used before traction of the threads. These patients had late removal of the urinary catheter due to the slightly more difficult mobilization caused by the presence of the suprapubic device, although early mobilization was obtained in all patients.

In patients who underwent Vecchietti's and Davydov's modified procedures, at 12 months after surgery the mean length and width of the neovagina were 7.5 ± 1.1 and 2.8 ± 0.6, and 8.5 ± 1.6 and 2.8 ± 0.65, respectively.

Compared with that obtained with Vecchietti's technique, Davydov's procedure allows the creation of a longer neovagina. Our data show a statistically significant difference in the neovaginal length both at hospital discharge (P = .008) and 12 months after surgery (P = .026) for the two groups. There was no statistically significant difference in neovaginal width (P > .05) (Table 1).

TABLE 2

Davydov vs. Vecchietti FSFI scores.

| Variable | Davydov (n = 40) | Vecchietti (n = 40) | P value |
|------------------|------------------|---------------------|---------|
| Desire | 4.3 ± 0.7 | 4.2 ± 0.9 | .8 |
| Arousal | 4.7 ± 0.8 | 4.6 ± 1 | .7 |
| Lubrication | 5.1 ± 0.6 | 4.5 ± 1 | .3 |
| Orgasm | 5 ± 0.6 | 4.4 ± 0.9 | .5 |
| Satisfaction | 4.8 ± 1.5 | 5.2 ± 1.2 | .6 |
| Comfort | 4.7 ± 1 | 5.2 ± 1 | .3 |
| Total FSFI score | 31.8 ± 0.8 | 30.2 ± 1 | .2 |

Note: Values are mean ± SD. A P value of < .05 is considered statistically significant.

Bianchi. Techniques and instrumentation. Fertil Steril 2011.

In one patient who underwent Davydov's procedure, an early and important fibrotic stenosis occurred at the margin between the peritoneum covering the neovagina and the mucosa of the vaginal introitus. Mechanical dilation of the neovaginal introitus was performed after 3 months in this case. Another patient presented with fever, pelvic pain, and a pelvic abscess after 5 months from the surgical procedure. This patient underwent explorative laparoscopy, during which purulent fluid was drained from the pelvis and the adnexae were freed from mild and filmy adhesions and neovaginal integrity was confirmed.

The neovagina was more rapidly coated by normal vaginal epithelium in those patients who underwent Davydov's procedure (at 6 months, 80% in the Davydov group and 60% in the Vecchietti group). Epithelization of the neovagina in patients at 12-months' follow-up was complete (100%) in both groups.

At 12 months after surgery all 80 patients were sexually active, and functional success was obtained as shown in Table 2, which shows both single domains and total scores, with no significant differences in either. Nonetheless, patient interviews at follow-up examinations identified 11 and 8 patients, respectively in the Davydov and the Vecchietti group, complaining of transient mild dyspareunia, which was at times superficial or deep. All patients had a partner for ≥ 3 months during the first 6-month follow-up period.

DISCUSSION

To our knowledge this is the first study comparing two surgical procedures performed by the same team for the creation of a neovagina in a relatively large cohort of patients with Rokitansky syndrome. This syndrome has known a wide variety of techniques proposed for the creation of a neovagina, demonstrating that "the inventiveness of the gynaecologic surgeons is infinite...and that the ideal procedure still has to be found" (8). Our experience compares the only two techniques that apply a laparoscopic approach and which we believe constitute a desirable combination of minimal invasiveness and good results.

As discussed in a previous study (9), the vaginal step makes Davydov's procedure particularly indicated for patients with abnormalities of the external genitalia, such as female hypospadias, which is a contraindication to the creation of a neovagina by vaginal pressure, such as in the laparoscopic Vecchietti technique and Frank method. Patients with a pelvic kidney were not assigned to Davydov's procedure group but rather to Vecchietti's procedure

(and therefore excluded from the study), owing to the risk of damaging the pelvic kidney or ureter during laparoscopic mobilization of the peritoneum. Similarly, previous pelvic surgery might be a relative contraindication to Davydov's technique because the presence of postoperative adhesions might complicate the surgical procedure and increase the risk of intraoperative complications.

Vecchietti's laparoscopic technique is definitely more simple and faster owing to its one laparoscopic step, whereas the modified Davydov's procedure also requires a perineal step, which can be complex.

Despite its simple technique, to obtain satisfying anatomic results Vecchietti's procedure requires special care in the graduation of the threads' tension, during which oral analgesia is usually needed for pain control. Davydov's approach immediately achieves satisfying anatomic results, and the use of dilators is needed to a lesser extent to maintain the end result. Anatomic outcomes of the two different techniques are comparable at 12-months' follow-up. Even if the difference in length seems to be statistically significant, there are no important differences in the sexual quality of life, as demonstrated by the FSFI, which showed a global optimal result in both groups. The process of re-epithelization of the neovagina occurs earlier in patients operated according to the Davydov technique, and although the reason for this is unclear, we might hypothesize that despite the peritoneum being dislocated, it preserves its original vascularization and therefore constitutes a more ideal substrate for epithelization than the pelvic connective tissue.

We experienced two patients with, respectively, an early stenosis at the neovaginal introitus and a pelvic abscess presenting after 5 months from the surgical procedure. A neovaginal introital stenosis has also been observed by Dargent et al. (8) in 4 of 28 patients operated with the same technique. The cause of this complication is unknown and has never been observed in patients undergoing Vecchietti's procedure. The other patient presenting with a pelvic abscess showed absence of dense or extensive abdominopelvic adhesions and no involvement of the pelvic organs. This patient's acute presentation of symptoms and intrapelvic condition would suggest a recently occurring infection, which most likely might have been due to a small neovaginal vault defect that could have been secondary to sexual intercourse, and which might have subsequently closed spontaneously.

Although in our series of 40 Davydov procedures no important intraoperative complications occurred, these can be severe, as explained by Soong et al. (6) and Dargent et al. (8), and are mainly represented by rectal and/or bladder perforations. An evident limitation to Davydov's technique occurs in cases of postoperative failure, which yield poor chances of surgical correction because recanalization of the urethra-vesico-rectal space becomes extremely difficult. On the other hand, in case of failure after Vecchietti's procedure, another technique can be attempted without major difficulties. In view of the possibility of offering uterine transplantation to these patients, the disruption of the pelvic anatomy caused by Davydov's approach might likely preclude this procedure, whereas Vecchietti's technique leaves the anatomy of the intrapelvic structures unaltered.

REFERENCES

1. Ohashi S, Ikuma K, Koyasu Y, Tei K, Kanno H, Akashi A, et al. Laparoscopic reconstruction of vagina using sigmoid autograft. *Surg Endosc* 1996;10:1019–21.
2. Ikuma K, Ohashi S, Koyasu Y, Tei K, Haque SM. Laparoscopic colpopoiesis using sigmoid colon. *Surg Laparosc Endosc* 1997;7:60–2.
3. Wan X, Xi X, Yan Q. Laparoscopic rectosigmoid colpopoiesis as a treatment for a patient with Mayer-Rokitansky-Kuster-Hauser syndrome. *Chin Med J (Engl)* 2003;116:1438–40.
4. Fedele L, Busacca M, Candiani M, Vignali M. Laparoscopic creation of a neovagina in Mayer-Rokitansky-Kuster-Hauser syndrome by modification of Vecchietti's operation. *Am J Obstet Gynecol* 1994;171:268–9.
5. Adamyan LV, Kulakov VIVI, Murvatov KD, Zurabiani Z. Application of endoscopy in surgery for malformations of genitalia. *J Am Assoc Gynecol Laparosc* 1994;1:S1.
6. Soong YK, Chang FH, Lai YM, Lee CL, Chou HH. Results of modified laparoscopically assisted neovaginoplasty in 18 patients with congenital absence of vagina. *Hum Reprod* 1996;11:200–3.
7. Rosen R, Brown C, Heiman J, Leiblum S, Meston C, Shabsigh R, et al. The Female Sexual Function Index (FSFI): a multidimensional self-report instrument for the assessment of female sexual function. *J Sex Marital Ther* 2000;26:191–208.
8. Dargent D, Marchiolè P, Giannesi A, Benchaib M, Chevret-Méasson M, Mathevet P. Laparoscopic Davydov or laparoscopic transposition of the peritoneal colpopoiesis described by Davydov for the treatment of congenital vaginal agenesis: the technique and its evolution. *Gynecol Obstet Fertil* 2004;32:1023–30.
9. Fedele L, Frontino G, Restelli E, Ciappina N, Motta F, Bianchi S. Creation of a neovagina by Davydov's laparoscopic modified technique in patients with Rokitansky syndrome. *Am J Obstet Gynecol* 2010;202:33.e1–6.

SUPPLEMENTAL MATERIALS

During the intervals considered, all patients admitted for the creation of a neovagina were systematically assigned to undergo Vecchietti's technique during the first recruitment period, whereas those recruited in the second period underwent Davydov's procedure. Fifteen patients who underwent the Vecchietti procedure from October 2003 to December 2004 and 30 patients who underwent the Davydov procedure from June 2005 to August 2008 were also included from two previously published studies (1, 2).

All 80 patients were diagnosed with Rokitansky syndrome before surgery. All had a normal female karyotype, amenorrhea, and normal secondary sexual characteristics, with absence of at least the upper two thirds of the vagina and of functioning median uterine structures.

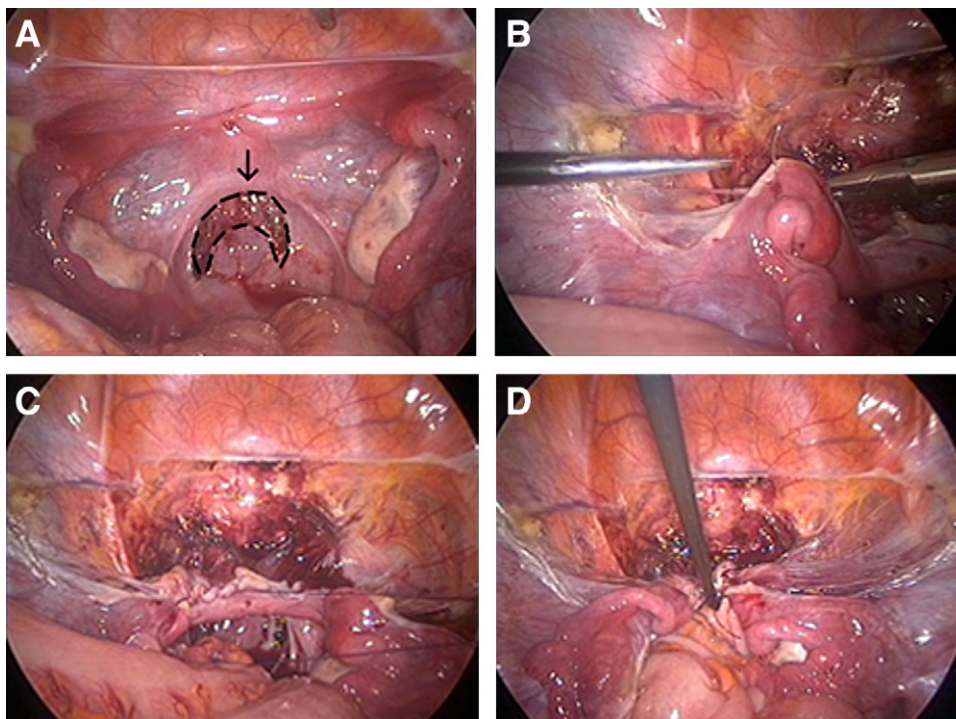
Modified Laparoscopic Davydov Technique

The modified laparoscopic Davydov technique involves a laparoscopic step followed by a perineal approach. During the laparoscopic step, after exploration of the pelvis and the abdominal cavity, the strand connecting the two rudimental uterine horns is lifted and the peritoneum immediately below is incised transversely, for a section of 4 to 5 cm. Guided by the index finger inserted in the patient's rectum, this incision is extended for approximately 1 cm into the connective tissue beneath which separates the bladder from the rectum (Supplemental Fig. 1A). To mobilize the perito-

neum, which will constitute the neovaginal walls and vault, the round ligaments are identified by applying traction on the uterine remnants and are then cut bilaterally (Supplemental Fig. 1B). The supravescical peritoneum is then incised along the apparent line that unites the rudiments. A monofilament (polydioxanone 3-0) is used to create two purse-string sutures for each hemipelvis. Each suture is begun from the mobilized peritoneum above the bladder dome, by consecutively transfixing the round ligament, the tubal isthmus, the utero-ovarian ligament, and the lateral peritoneal leaf before identification of the ureters (Supplemental Fig. 1C). The two sutures then include the lateral aspect of the mesorectum and end including the anterior aspect of the rectum immediately below the rectosigmoid junction (Supplemental Fig. 1D). The perineal step creates an anastomosis between the previously incised pelvic peritoneum and the mucosa of the vaginal vestibulum. An H-shaped incision is made on the vaginal vestibulum, with a transverse cut from the base of one minor labia to the contralateral and two vertical cuts running laterally at the extremities of the transverse incision (Supplemental Fig. 2A). The dissection between the bladder and rectum is started along the vertical incisions, creating two paramedian tunnels, whereas the median raphe is cut subsequently. The surgeon works by blunt and sharp dissection and finally identifies the peritoneal margins of the laparoscopically performed transverse incision. The peritoneal margins are then hooked by interrupted polydioxanone 3-0 sutures to the vestibulum's mucosa, starting from the median line where mobilization of the margins is easiest (Supplemental Fig. 2B). When the anastomotic suture is completed,

SUPPLEMENTAL FIGURE 1

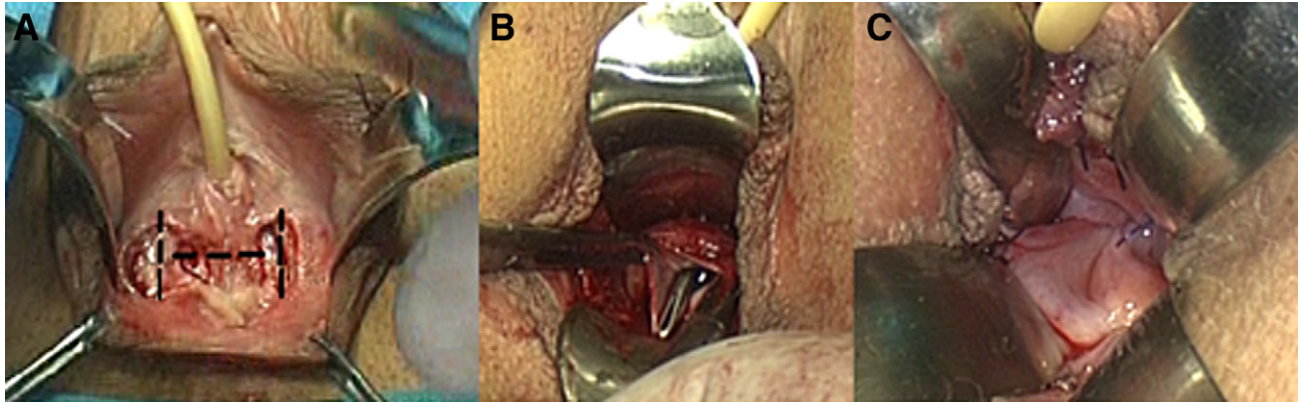
Creation of two purse-string sutures for each hemipelvis. (A) The peritoneum immediately below the connecting strand is incised transversely for a section of 4 to 5 cm, extending it for approximately 1 cm into the connective tissue beneath (dotted line). (B) Transfixion of the round ligament. (C) Creation of the left purse-string suture by transfixing consecutively the round ligament, the tubal isthmus, the utero-ovarian ligament, the lateral peritoneal leaf, and the rectal serosa. (D) Closure of the right purse-string and final laparoscopic vision.



Bianchi. Techniques and instrumentation. Fertil Steril 2011.

SUPPLEMENTAL FIGURE 2

Perineal step. (A) H-shaped incision is made on the vaginal vestibulum (*dotted line*). (B) Pelvic peritoneum is identified before creation of an anastomosis with the vaginal vestibulum. (C) Final vision of neovagina covered by peritoneum.



Bianchi. *Techniques and instrumentation. Fertil Steril* 2011.

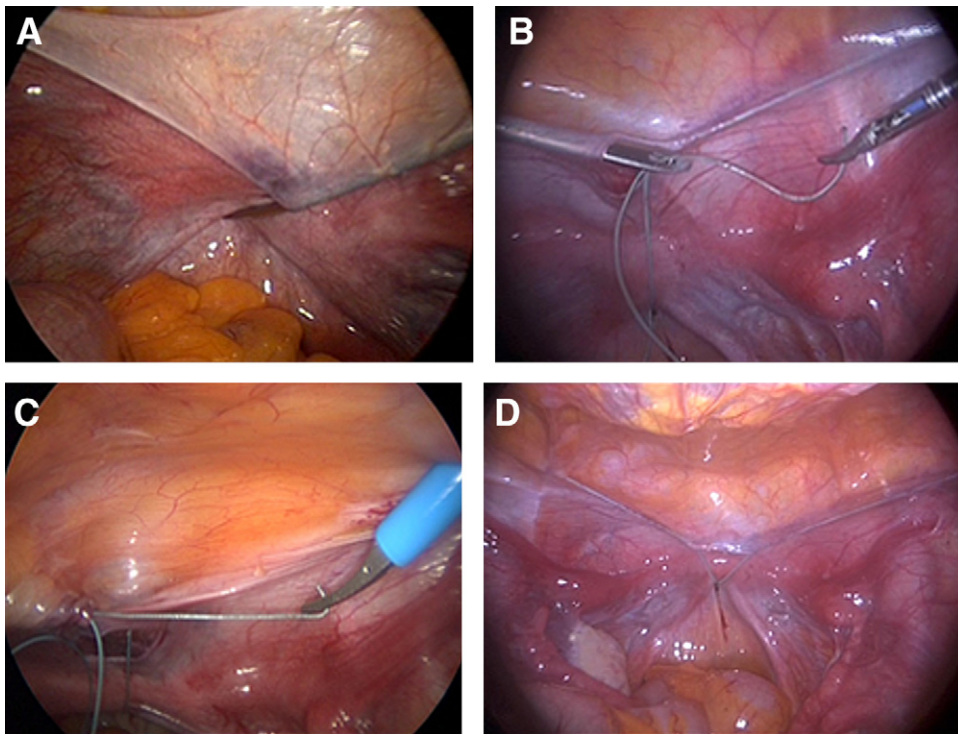
a paraffin gauze dressing tampon is inserted in the peritoneum-coated neovagina. (Supplemental Fig. 2C). Removal of the urinary catheter and tampon and use of vaginal dilators was planned for 48 hours after surgery.

Modified Laparoscopic Vecchietti Technique

After the bladder is emptied by catheterization, adequate pneumoperitoneum is obtained and a laparoscope is introduced by the transumbilical route. The traction device is temporarily placed on the

SUPPLEMENTAL FIGURE 3

(A) Thread-bearing needle is brought out of the peritoneal cavity and reinserted in the subperitoneum immediately below the uterine rudiment. (B) Pseudohymen is perforated centrally, and the threads attached to the mobile dummy are hooked. (C, D) While the needle is withdrawn from the abdomen, the threads are brought into the peritoneal cavity and are then both guided outward and subperitoneally through the abdominal wall.



Bianchi. *Techniques and instrumentation. Fertil Steril* 2011.

suprapubic region, and the points at which the threads will pass are marked on the skin. Adjacent to the markings, two ancillary trocars are introduced to allow accurate exploration of the abdominal and pelvic organs. The trocars are then removed, and one is replaced by Vecchietti's straight thread-bearing cutting needle, which is passed through the loose subperitoneal connective tissue downward and medially until it has reached the fold between the bladder and uterine rudiment. Because it is difficult to separate the peritoneum from the rudiment, the thread-bearing needle is brought out of the peritoneal cavity and reinserted in the subperitoneum immediately below the uterine rudiment (Supplemental Fig. 3A). At this point, the direction is changed from lateromedial to craniocaudal so that the cutting needle crosses the space between the bladder and rectum and reaches the pseudohymen. Before perforating the pseudohymen, the laparoscopist should guide the tip of the instrument aided by the middle finger inserted in the rectum. The pseudohymen is perforated centrally, and the threads attached to the mobile dummy are hooked (Supplemental Fig. 3B). As the needle is withdrawn, the threads are brought back into the peritoneal cavity and are then both brought outward and passed subperitoneally through the abdominal wall (Supplemental Fig. 3C and D). In the last stage of the procedure the threads are attached to the traction device, and their tension is graduated. Bladder and rectal integrity are systematically checked with a cystoscopic and rectoscopic control.

The traction device and mobile dummy are removed after the neovagina has progressed to at least 7 to 8 cm in depth, which may be obtained between the sixth and ninth day after surgery. Patients could be potentially discharged from the hospital 48–72 hours after surgery and subsequently seen every 48 hours so as to adjust the thread tension. Adequate analgesic therapy is usually necessary immediately before adjusting the thread tension.

After removal of the device and dummy, all patients were instructed to use dilators, starting with the smallest and keeping it inserted in the neovagina for approximately 8–10 hours per day during the first month. Although various types of dilators are available, we recommend those that are soft and blunt. The decision to progress to a larger dilator was made by the physician at follow-up examination.

The two surgical procedures were compared in terms of parameters reflecting safety, effectiveness, and compliance, which were

systematically measured for all patients. The use of analgesics was defined as total days of administrations of analgesic drugs, namely ketoprofene (160 mg IV or IM), from the first postoperative day to hospital delivery. Vaginal bleeding was assessed by the mean number of saturated pads changed per day during the hospital stay. Two patients who lived close enough to our hospital department came in every other day to graduate the tension of the threads and had been respectively discharged 72 and 96 hours postoperatively.

The Female Sexual Function Index (FSFI) assesses six domains: desire, arousal, lubrication, orgasm, satisfaction, and pain. The functional result is considered to be very good when the FSFI score is >30, good between 23 and 29, and poor when the sum is <23. The highest total FSFI score that may be obtained is 36. The mean score \pm SD for all parameters compared and summarized in Tables 1 and 2 (main text) was calculated, and the comparison between the two groups was done using the *t* test. A *P* value of <.05 was considered statistically significant.

We systematically performed vaginoscopy with Schiller's test to evaluate the epithelization of the neovagina in all the patients 6 and 12 months after surgery.

This study is limited owing to its nonrandomized nature. However, anatomic characteristics (i.e., female hypospadias, pelvic kidneys) of Mayer-Rokitansky-Küster-Hauser syndrome do not allow adequate randomization. In addition, although our hospital is a referral center, Rokitansky syndrome is rare; therefore, an adequate case series for this type of study cannot be obtained in a reasonable period. However, the comparison made in this study yields some interesting points.

The decision as to which is the best approach for each patient should obviously be made primarily after an accurate medical history, along with assessment of the external genitals as well as intrapelvic evaluation during the laparoscopic step. The laparoscopic approach of both techniques allows very good aesthetic results, with both minimal invasiveness and scarring in these young patients. In conclusion, on the basis of our experience, both Davydov's and Vecchietti's laparoscopic technique seem to yield optimal anatomic and functional results in the treatment of vaginal agenesis in Rokitansky syndrome.

REFERENCES

1. Fedele L, Bianchi S, Frontino G, Fontana E, Restelli E, Bruni V. The laparoscopic Vecchietti's modified technique in Rokitansky syndrome: anatomic, functional, and sexual long term results. *Am J Obstet Gynecol* 2008;198:377.e1–6.
2. Fedele L, Frontino G, Restelli E, Ciappina N, Motta F, Bianchi S. Creation of a neovagina by Davydov's laparoscopic modified technique in patients with Rokitansky syndrome. *Am J Obstet Gynecol* 2010;202:33.e1–6.